

A case report of genital tuberculosis resulting in Asherman's syndrome and infertility

Hale Teka¹, Awol Yemane¹, Biniyam Mohammedburhan², Ephrem Berhe³, Fithanegest Mamo¹, Yibrah Berhe¹

¹Department of Obstetrics and Gynecology, Ayder Comprehensive Specialized Hospital

²Department of Pathology, Ayder Comprehensive Specialized Hospital

³Department of Internal Medicine, Ayder Comprehensive Specialized Hospital

Corresponding author: E-mail: haleteka@gmail.com

Abstract

Background

Tuberculosis can affect any organ in the body. Genital tuberculosis is generally rare. The relative rarity and lack of cardinal symptoms of female genital tuberculosis results in diagnosis delays.

Case detail

A 26-year-old primipara mother presented to our hospital with amenorrhea and infertility. With the clinical impression of Asherman's syndrome, Dilatation and curettage (D and C) was done and tissue was sampled for histopathology. The sampled endometrial tissue showed extensive necrosis, nodular aggregates of epithelioid granulomas, and Langhan's type giant cells which are prototype of mycobacterium tuberculosis. She was subsequently put on anti-tubercular medications and copper intrauterine device (ParaGard) to avoid adhesion reformation. Three months into her treatment, she started to have monthly vaginal spotting heralding the resumption of menses. Six months later she began to have a regular menses.

Conclusion

Genital tuberculosis remains a significant cause of infertility in developing countries. Physicians should maintain high index of suspicion for genital tuberculosis in developing countries with high tuberculosis burden.

Key words: Genital Tuberculosis, endometrial Tuberculosis, *Mycobacterium Tuberculosis*, secondary amenorrhea, infertility

Introduction

More than a century after its isolation and description as a disease-causing organism, mycobacterium tuberculosis still remains a global health problem and is responsible for maximum number of deaths in adults from a single infectious agent (1,2). One in 10 of infected individuals belong to the developing countries and 3/4th of these infected individuals are the economically productive age group (3,4). Ethiopia ranks third in Africa and eighth among the 22 highest tuberculosis (TB) burdened countries in the world (5). The prevalence of all forms of TB is estimated at 261 per 100 000 population, leading to an annual mortality rate of 64 per 100 000 population (5). The incidence rate of all forms of TB is estimated at 359 per 100 000 population (5).

Tuberculosis can affect any organ in the body; can exist without any clinical manifestation; and can recur. Genital tuberculosis (TB) is rare in low endemic areas but is relatively common in developing countries particularly in communities where pulmonary or other forms of extragenital TB are common (6,7). However primary Genital TB is uncommon (7). Genital TB is almost always secondary to TB elsewhere in the body—usually pulmonary and sometimes

renal, gastrointestinal, bone, or joint; occasionally it is part of a generalized military disease process (6).

Female genital TB is a significant aetiologic factor of infertility in regions of high TB prevalence (8,9). Genital tuberculosis in developed countries are often seen in women immigrated from developing countries (6,10).

Female genital tuberculosis (FGTB) is an important gynecological problem in Ethiopia where pulmonary TB is prevalent (8).

However, endometrial TB is rarely diagnosed and reported in low resource setting. To showcase the delays related to the relative rarity and confusing clinical presentations of endometrial TB and with the intention of informing clinicians to maintain a high index of suspicion for genital TB in set ups with high TB prevalence, we report the following case report.

Case Report

We report a 26-year-old primipara mother who presented to our hospital with amenorrhea and secondary infertility. She gave birth vaginally 9 years back and she was on injectable contraceptives for 4 years.

Planning to conceive, she discontinued the injectable contraceptive 5 years back. Currently came to our center complaining of failure to conceive of 5 years and amenorrhea of 9 years duration. She was relatively well previously. She has no symptom complex of tuberculosis. She also claims to have no close contact with a patient with active pulmonary tuberculosis disease or history of tuberculosis disease treatment to herself. She was put on oral contraceptives previously for the management of amenorrhea but did not see menses with the management.

Hormonal work up for infertility was unremarkable. Sperm analysis of her partner was normal. Chest X-ray was normal. Her HIV test was negative.

She was admitted to our hospital and short of hysteroscopy, D& C was done for the impression of secondary amenorrhea secondary to Asherman's syndrome. Tissue was subjected to histopathology and histopathology exam showed features pertinent to endometrial tuberculosis. (See figures 1-3 acquired at the Department of Pathology in Mekelle University, College of Health Sciences). She was subsequently put on anti-tubercular medications 2(RHZE)/4(RH) and copper intrauterine device

(ParaGard) to avoid adhesion reformation. Three months into her treatment, she began to have spotting heralding the resumption of her menses. Six months later, she began to have regular menses.

Discussion

Female genital TB is a chronic disease with low-grade symptoms (11). The clinical presentation of patients with female genital tuberculosis may vary from asymptomatic to non-specific pelvic symptoms (12). If symptomatic, female patients usually present with symptoms like menstrual dysfunction, pelvic masses, pelvic/abdominal pain, and infertility (12, 13, 14). Genital TB affecting the endometrium often present with Asherman's syndrome; a clinical condition where intrauterine adhesion leads to menstrual dysfunction, amenorrhea, and infertility (10). Some patients can also present with vaginal discharge and irregular firm cervix with contact bleeding confusing for cervical cancer (15). Patient work up helpful for the diagnosis of genital tuberculosis are pelvic ultrasonography, hysterosalpingo-graphy, hysteroscopy and laparoscopy. Confirmatory tests include TB-PCR, microbiologic studies on endometrium and endometrial histopathology (16-18).

Its aetiopathogenetic diagnosis can be reached by combining the clinical findings with histopathology and laboratory investigations (PCR and/or positive culture for *Mycobacterium tuberculosis* (4,11).

Hysteroscopic visualization of tuberculous endometritis may reveal varying grades of endometrial cavity obliteration with adhesion bands, small and shrunken cavity, inability to distend the endometrium during the procedure and increased complications of the procedure (18). Laparoscopy and hysteron-sonography has limited value in the diagnosis of tuberculous endometritis. They can, however, help to rule out adnexal tuberculous (18).

Endometrial biopsy requires concern and a higher precision in the diagnosis of this insidious disease that primarily necessitates a clinical awareness of this serious health problem (9, 16).

The commonest site affected by female genital tuberculosis is the fallopian tubes (100%), followed by endometrium (50%), ovaries (20%), cervix (5%), and vagina and vulva in (<1%) (11). The patients present with infertility, pelvic pain, abnormal vaginal bleeding, amenorrhea, and vaginal discharge in 44%, 25%, 18%, 5%, 4% cases respectively (11). Some patients can also present with vaginal discharge and irregular

firm cervix with contact bleeding confusing for cervical cancer (19).

Tuberculous endometritis has been observed in 13.6% of infertile women undergoing routine endometrial biopsy, but a negative endometrial biopsy does not rule out genital TB since TB endometritis is seen in only 50–60% of cases (20). The prevalence of FGTB in infertility clinics shows marked variations in different countries ranging between 1 and 19%: 0.69% in Australia, 0.07% in the United States, less than 1% in Finland, 4.2% in Saudi Arabia, 5.6% in Scotland, and 19% in India (7,8). Only scattered case reports exist in Ethiopia.

The culprit in female genital tuberculosis in developing is delay in diagnosis (21). Early diagnosis is usually difficult because significant numbers of women are asymptomatic and if symptomatic, symptoms are nonspecific. Physicians also have low index of suspicion for genital tuberculosis contributing for delay in diagnosis and adverse short- and long-term consequences (8). Patients with no complaint in other common primary tuberculosis diseases sties, like in our case, pose difficulty in diagnosis. Early diagnosis and prompt treatment of tuberculosis (TB) is

vitaly important as it greatly reduces disease and treatment-related morbidity and even mortality in extreme cases (21).

Multiple drug therapy in adequate doses and for sufficient duration is the main stay in the treatment of TB including FG TB. Short-course chemotherapy for 6–9 months has been found to be effective for medical treatment of female genital tuberculosis. Six months therapy is equally effective to 9 months therapy (21).

Conclusion

Genital tuberculosis remains a significant cause of infertility in developing countries. Physicians should maintain high index of

suspicion for genital tuberculosis in developing countries with high tuberculosis prevalence. Clinicians have to lower their threshold especially for patients presenting with infertility and amenorrhea. Combining clinical findings with histopathologic and laboratory findings is prudent for confirmation of the etiologic agent.

Conflict of interest

The authors declare that there is no conflict of interest regarding the publication of this paper.

Funding

No fund was solicited for this work

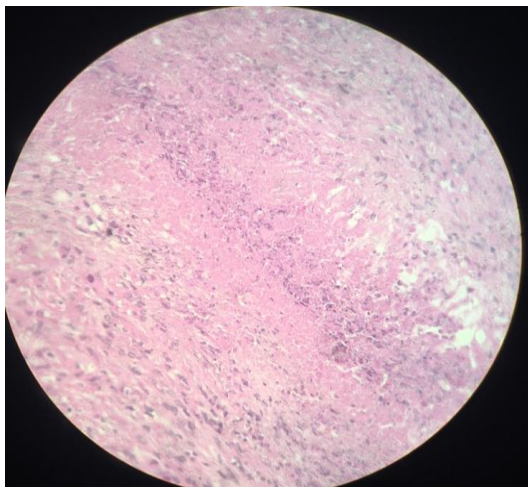


Figure 1: High power microscopy (40x) shows extensive necrosis which helps to reach to a diagnosis of tuberculosis

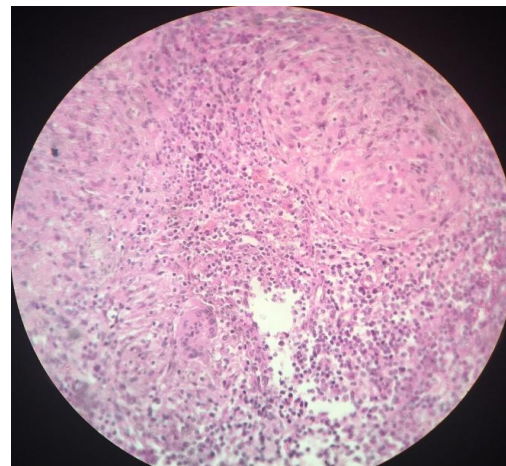


Figure 2: High power microscopy (40x) displays epithelioid granulomas and Langhan's type giant cells

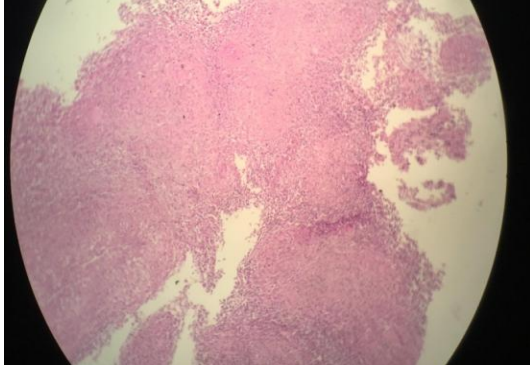


Figure 3: 10X power light microscopy showing nodular aggregates of epithelioid granulomas and Langhan's type giant cells

References

1. Yadav S, Singh P, Hemal A, Kumar R. Genital tuberculosis: Current status of diagnosis and management *Transl Androl Urol* 2017;6(2):222-233. doi: 10.21037/tau.2016.12.04
2. Raviglione MC, Snider DE Jr, Kochi A. Global epidemiology of tuberculosis. Morbidity and mortality of a worldwide epidemic. *JAMA* 1995;273:220-6.
3. WHO. Global Tuberculosis report 2015. Available online: http://apps.who.int/iris/bitstream/10665/191102/1/9789241565059_eng.pdf?ua=1
4. Abbara A, Davidson RN. Etiology and management of genitourinary tuberculosis. *Nat Rev Urol* 2011;8:678-88.
5. World Health Organization: *Analytical Summary - Tuberculosis* http://www.aho.afro.who.int/profiles/information/index.php/Ethiopia:Analytical_summary_-_Tuberculosis, 2014.
6. Kocher, C., R. Weber, and A. Friedl, *A case study of female genital tuberculosis in a Western European setting*. *Infection*, 2011. **39**(1): p. 59-63.
7. Varma, T.R., *Tuberculosis of the Female Genital Tract*. Glob. libr. women's med, 2008.
8. Abebe, M., et al., *Female genital tuberculosis in Ethiopia*. *Int J*

- Gynaecol Obstet, 2004. **84**(3): p. 241-6.
9. Sharma, J.B., et al., *Genital tuberculosis: an important cause of Asherman's syndrome in India*. Arch Gynecol Obstet, 2008. **277**(1): p. 37-41.
 10. Mary louise, Shurit Mahaligaiah. Case report of pelvic tuberculosis resulting in Asherman's syndrome and infertility. Fertility Research and Practice. (2019) 5:8; <https://doi.org/10.1186/s40738-019-0061-0>
 11. Das P, Ahuja A, Gupta SD. Incidence, etiopathogenesis and pathological aspects of genitourinary tuberculosis in India: A journey revisited. Indian J Urol 2008; 24 : 356-61.
 12. Suman K. Jaha, Balram Rathish. Genitourinary Tuberculosis. StatPearls Publishing. 2022. Bookshelf ID: NBK557558 PMID: 324991490
 13. Bettaiah R, Daksha S, Ghanti R, Balakrishnan D. Female genital tuberculosis – still a common cause of primary amenorrhea in developing countries. Int J Reprod Contracept Obstet Gynecol 2016;5:2891-4.
 14. Sharma JB, Roy KK, Pushparaj M, et al. Genital tuberculosis: an important cause of Asherman's syndrome in India. Arch Gynecol Obstet. 2008;277:37.
 15. H Lamba, et al., *Tuberculosis of the cervix: case presentation and a review of the literature*. Sex Trans Inf, 2002. **78**: p. 62-63.
 16. Jindal, U.N., et al., *Female genital tuberculosis: early diagnosis by laparoscopy and endometrial polymerase chain reaction*. Int J Tuberc Lung Dis, 2010. **14**(12): p. 1629-34.
 17. Sharma, J.B., Current Diagnosis and Management of Female Genital Tuberculosis. J Obstet Gynaecol India, 2015. 65(6): p. 362-71.
 18. Harzif AK, Anggraeni TD, Syaharutsa DM, Hellyanti T. Hysteroscopy role for female genital tuberculosis. Gynecol Minim Invasive Ther 2021;10:243-6.
 19. Bekele, D. and Y. Bekuretsion, *Tuberculosis of the cervix mimicking cervical cancer*. Ethiop Med J, 2014. **52**(2): p. 87-9.
 20. Dadhwal, V., et al., *Flare-up of genital tuberculosis following endometrial aspiration in a patient*

of generalized miliary tuberculosis.
Arch Gynecol Obstet, 2009. **280**(3):
p. 503-4.

21. Bhagwan Sharma, J., et al., *Effect of
Antitubercular Therapy on
Endometrial Function in Infertile*

*Women with Female Genital
Tuberculosis.* Infect Disord Drug
Targets, 2016. **16**(2): p. 101-8.

